

RANZCO Referral Pathway for AMD Screening and Management by Optometrists

Preamble
 The treatment for neovascular AMD is now well established so that timely referral is essential for best visual outcome. Earlier Stages of AMD and Geographic Atrophy (GA) remain untreatable.

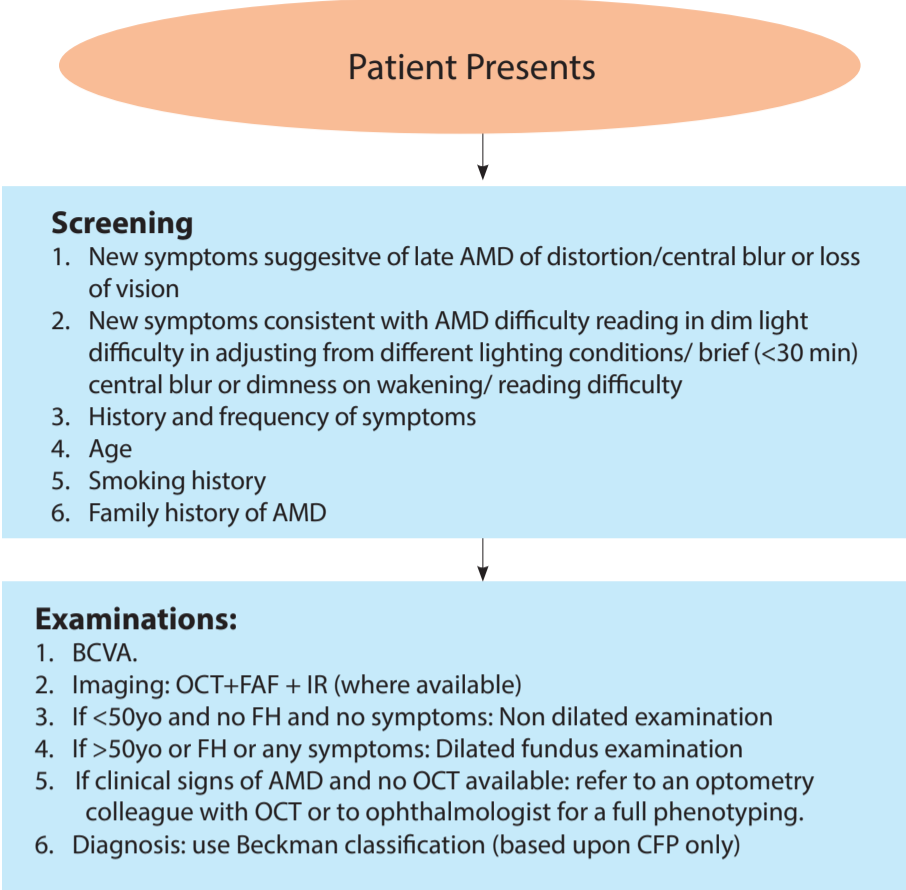
We are currently in a state of rapid change in our understanding and classification of these forms of AMD as we learn more about risk of progression to vision loss from multi modal imaging.

As such it is imperative to remain up to date on the interpretation of novel imaging modalities and the currently recruiting trials in Australia so that optometrists can offer appropriate referral for participation in trials where new treatments are being trialed.

There has never been a more important time for all clinicians to use the same terminology for AMD as we start to have stage specific interventions and as we depend more and more on optometrists to identify appropriate people for screening for these current and future trials. The 2013 Beckman classification should be used*

It is hoped that these referral guidelines will enhance these endeavours.

* Ferris FL, Wilkinson CP, Bird A, Chakravarthy U, Chew EY, Csaky K, Sadda SR, on behalf of the Beckman Initiative for Macular Research Classification Committee. Clinical Classification of Age-Related Macular Degeneration. Ophthalmology 2013; 120 (4) 844-851.



Footnotes

1. First time identified GA:
 - Baseline OCT, IR, and FAF data will help to predict progression.
 - Reticular Pseudodrusen (RPD) imply a faster rate of growth of GA so therefore imaging to determine their presence will help advise the patient.
2. Bilateral GA: CNV can still develop with further loss of vision so review any sudden onset of worsening symptoms and refer as per referral pathway if CNV cannot be excluded.
3. Medicare only reimburses every 3 years for a normal review, however several bodies recommend every 2 years

Abbreviations

BCVA – Best corrected visual acuity
CNV – Choroidal neovascularization
FAF – Fundus Autofluorescence
FH – Family history (of AMD)
GA – Geographic atrophy
IR – Infra-red
IRC – Intra-retinal cysts
OCT – Optical coherence tomography
RPD – Reticular Pseudodrusen
SRF – Sub-retinal fluid

